

## Left Bundle-Branch Block

Left bundle-branch block (LBBB) is a condition that occurs when the electrical impulses traveling through the left bundle branch become slowed or blocked. The right ventricle (RV) receives the electrical impulse first, causing the left ventricle (LV) to contract slightly after the RV contracts. LBBB often is a marker for coronary heart disease, cardiomyopathy, long-standing hypertension, and severe aortic valve disease.<sup>1</sup> On electrocardiogram (ECG), the peak of the QRS complex is notched in patients with LBBB<sup>2</sup> (Figure 1).

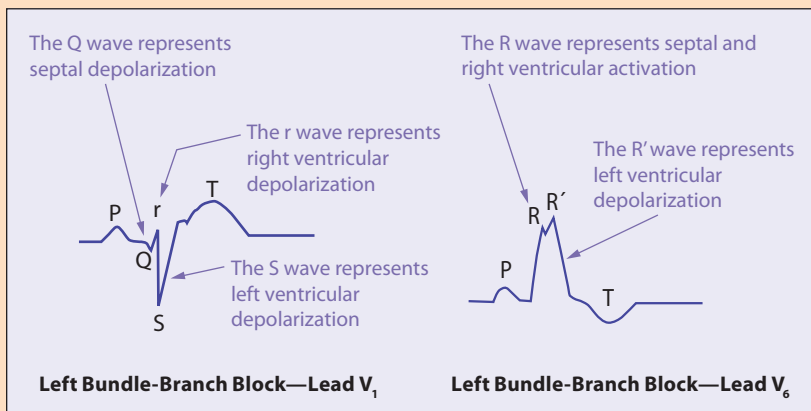


Figure 1. Detailed representation of surface ECG in patients with LBBB.<sup>3</sup>

### LBBB AND FALSE-POSITIVE DEFECTS WITH EXERCISE

Patients with LBBB have asynchronous ventricular contraction that worsens with exercise.<sup>4,5</sup> During exercise myocardial perfusion imaging (MPI), images from patients with LBBB often display false-positive defects similar to those caused by coronary artery disease (CAD)<sup>4</sup> (see Figures 2a and 2b). Because reversible septal perfusion defects, mimicking septal ischemia, are common in non-CAD patients with LBBB who are stressed with exercise (Figure 3), pharmacologic stress testing has become the preferred method of MPI in patients with LBBB.<sup>6</sup>

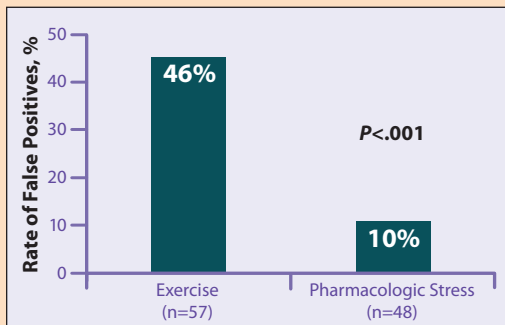


Figure 3. False-positive rates for septal defects with exercise and pharmacologic stress testing.<sup>4</sup>

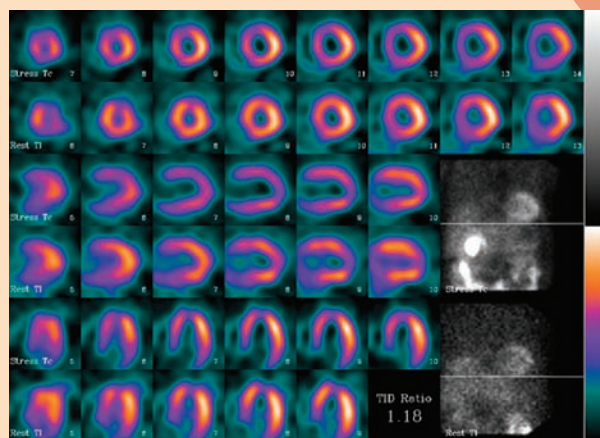


Figure 2a.

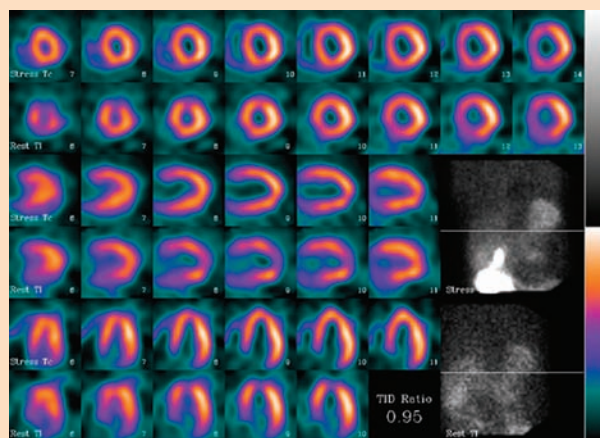


Figure 2b.

Figure 2a. Treadmill images for a 63-year-old male with no history of CAD who had been diagnosed as having an LBBB. These images show a reversible perfusion defect in the anteroseptal wall, accounting for 30% of the total left ventricular (LV) myocardium. This exercise SPECT study was technically suboptimal. Figure 2b. Pharmacologic stress images in the same patient, showing a mild fixed perfusion defect in the septal wall, accounting for 7% of total LV myocardium. These results were interpreted as probably normal. Pharmacologic stress demonstrated benefit over exercise stress in this patient with LBBB. Based on the exercise stress test results alone, this patient may have been incorrectly diagnosed as having CAD because a large reversible septal defect was noted on imaging.

## UTILITY OF PHARMACOLOGIC STRESS FOR LBBB

In patients with LBBB, pharmacologic stress imaging has been associated with fewer false-positive defects. Several studies have indicated the clinical value of pharmacologic stress MPI in patients with pre-existing LBBB.<sup>7-9</sup> Wagdy et al<sup>7</sup> evaluated 245 patients with LBBB who underwent thallium or sestamibi SPECT with pharmacologic stress with a vasodilator. As shown by pharmacologic stress imaging, survival rates were significantly higher in low-risk patients versus high-risk patients (Figure 4). The authors concluded that MPI with pharmacologic stress provides important prognostic information in patients with LBBB. The clinical utility of pharmacologic stress in LBBB patients with hypertension has also been shown.<sup>9</sup>

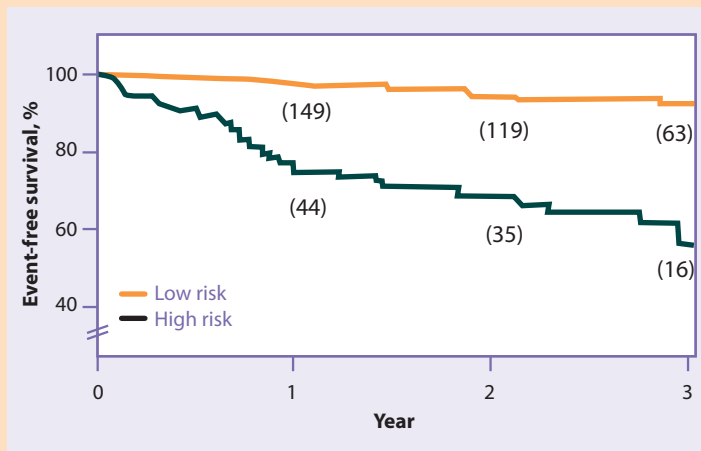


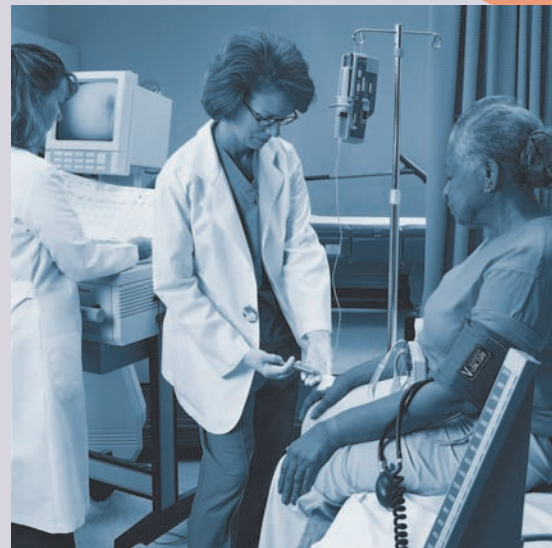Figure 4. Prognostic value of vasodilator SPECT in LBBB.<sup>7</sup>

## CONCLUSION

LBBB usually causes a perfusion defect that is restricted to the septum. Because the decrease in septal blood flow in patients with LBBB seems to be dependent on heart rate, it is suggested that pharmacologic stress may help prevent this physiologic artifact in patients with LBBB who are referred for a myocardial perfusion study.

### References

1. Goldberger AL. Electrocardiography. In: Kasper DL, Braunwald E, Fauci AS, et al, eds. *Harrison's Principles of Internal Medicine*. 16th ed. The McGraw-Hill Companies; 2007. Available at: [www.accessmedicine.com](http://www.accessmedicine.com). Accessed April 2, 2007.
2. Crawford ES, Husain SS. Fundamentals of Electrocardiography. In: *Nuclear Cardiac Imaging. Terminology and Technical Aspects*. Reston, Va: Society of Nuclear Medicine; 2003:116.
3. Mart C. Bundle branch block, left. Available at: <http://www.emedicine.com/ped/topic2501.htm>. Accessed April 11, 2007.
4. Vaduganathan P, He Z-X, Raghavan C, Mahmarian JJ, Verani MS. Detection of left anterior descending coronary artery stenosis in patients with left bundle branch block. exercise, adenosine or dobutamine imaging? *J Am Coll Cardiol*. 1996;28:543-550.
5. Bramlet DA, Morris KG, Coleman RE, Albert D, Cobb FR. Effects of rate-dependent left bundle branch block on global and regional left ventricular function. *Circulation*. 1983;67:1059-1065.
6. Berman DS, Hachamovitch R, Germano G. Risk stratification and patient management. In: Dilsizian V, Narula J, eds. *Atlas of Nuclear Cardiology*. 2nd ed. Philadelphia, Pa: Current Medicine LLC; 2003:150.
7. Wagdy HM, Hodge D, Christian TF, Miller TD, Gibbons RJ. Prognostic value of vasodilator myocardial perfusion imaging in patients with left bundle-branch block. *Circulation*. 1998;97:1563-1570.
8. Lebtahi NE, Stauffer JC, Delaloye AB. Left bundle branch block and coronary artery disease: accuracy of dipyridamole thallium-201 single-photon emission computed tomography in patients with exercise anteroseptal perfusion defects. *J Nucl Cardiol*. 1997;4:266-273.
9. Feola M, Biggi A, Ribichini F, Camuzzini G, Uslenghi E. The diagnosis of coronary artery disease in hypertensive patients with chest pain and complete left bundle branch block: utility of adenosine Tc-99m tetrofosmin SPECT. *Clin Nucl Med*. 2002;27:510-515.



**“Our findings clearly indicate that pharmacologic stress imaging is associated with fewer false-positive septal perfusion defects in patients with left bundle branch block, thereby improving the specificity of perfusion scintigraphy for left anterior descending coronary artery stenosis.”**

—Vaduganathan P, et al.

*J Am Coll Cardiol*. 1996;28:543-550.

For interactive *Tech Tips* and more, visit [pharmstresstech.com](http://pharmstresstech.com).

Provided as an educational service by **Astellas Pharma US, Inc.**  
**COMMITTED TO CARDIOLOGY®**