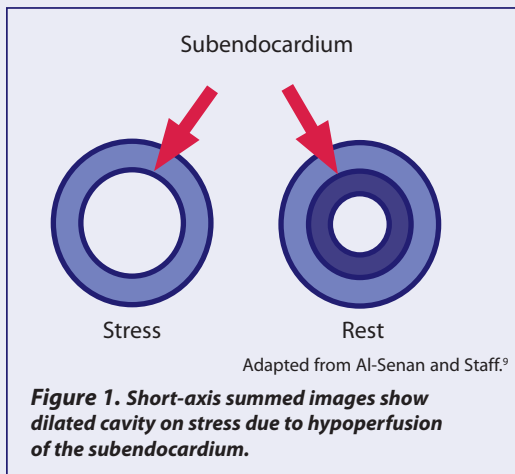


Transient Ischemic Dilation

Myocardial perfusion imaging (MPI) can sometimes produce false-negative results in patients with multivessel coronary artery disease (CAD). When multiple arteries are occluded to an equivalent degree (ie, “balanced” ischemia), the perfusion defects that occur during stress imaging may be generally uniform in severity throughout the myocardium. As a result, radiotracer uptake will also be uniform, leading to a false-negative examination.^{1,2}

A finding of transient ischemic dilation (TID) on stress MPI (either exercise or pharmacologic) is valuable in such situations because it enables clinicians to identify patients with multivessel CAD despite otherwise normal MPI results.^{3,4} It also can be useful for risk stratification by serving as a clinically useful marker for severe and extensive disease,⁵ and as a predictor of future cardiac events.^{4,6}

TID is found to be present when the diameter of the left ventricle (LV) cavity appears larger on poststress images as compared with resting images. It is most likely due to stress-induced subendocardial ischemia (a lack of blood supply to the innermost layer of the ventricle).⁷ Underperfusion of the subendocardium region causes the LV’s enlarged appearance rather than actual dilation (Figure 1).⁸⁻¹⁰



TID may also result from physical dilation (true dilation of the LV throughout the cardiac cycle, also caused by ischemia),^{11,12} or from systolic dysfunction (in which LV stunning decreases the ejection fraction at stress, thereby increasing ventricle size).¹³ But even if the underlying cause of TID is not completely understood, the finding of TID has been shown to be a clinically useful marker for severe and extensive CAD.⁵

TRANSIENT ISCHEMIC DILATION PREDICTS EXTENSIVE CAD

Abnormal TID has correlated better with the presence of multivessel CAD than have multiple perfusion abnormalities and visual summed stress scores.^{5,12,14} It is a more sensitive and specific marker for multivessel CAD than other common markers during stress testing, such as a patient’s limited ability to exercise and severe ST-segment depression (>2 mm).¹² And patients with TID are more likely to have a cardiac event (nonfatal myocardial infarction or cardiac death) than those without TID.⁶

Numerous studies have demonstrated that a finding of TID on stress MPI is predictive of extensive CAD (often confirmed by angiography), as well as significantly increased cardiac events (Table 1).

Table 1.

STUDY	SELECTED RESULTS/ CONCLUSIONS
Weiss et al. ¹²	The TID ratio is an easily derived and highly specific marker of multivessel CAD.
Mazzanti et al. ⁵	TID assessment showed high sensitivity (71%) and very high specificity (95%) for severe and extensive CAD.
McClellan et al. ⁶	The cardiac event rate was 1.9% in patients without TID versus 11.4% in those with TID.
Kinoshita et al. ³	The TID index was significantly greater in patients with a greater number of occluded coronary vessels ($P<0.01$).
Abidov et al. ⁴	TID yielded incremental prognostic value over clinical and historical variables in patients with otherwise normal MPI results.
Abidov et al. ¹⁴	Integrating abnormal TID ratios within MPI interpretation greatly improved identification of severe and extensive CAD in patients undergoing pharmacologic stress MPI.

ASSESSING TID

TID is relatively easy to detect. The size of the LV is measured during stress and again at rest—often with automated software—and a ratio of the 2 measurements is computed. TID is present when the ratio falls above a “normal” limit that has ranged from 1.12 to 1.36 in various studies.^{5,12-14}

It has been shown that the TID ratio is generally higher with pharmacologic stress than with exercise stress.¹⁵ A TID threshold of 1.22 or greater has been validated as having the highest sensitivity and specificity for detecting severe and extensive CAD in patients undergoing exercise stress.⁵ To detect severe and extensive disease with adenosine stress, a TID threshold of greater than 1.36 has been documented.¹⁴ The exact reason for such a difference in TID thresholds is not clearly understood, but this difference is consistent with clinical observations.¹⁵

TID has been reported in 8% to 37% of patients, depending on the patient population, stress modality, radioisotope, test protocol, and TID criteria.^{6,10,16,17} Certain patient characteristics can signal a higher likelihood of TID. In a recent study of 1560 patients with otherwise normal MPI results, those with TID tended to be older, included more women, were less able to perform exercise, and more often had diabetes.⁴

TID IN PATIENT MANAGEMENT

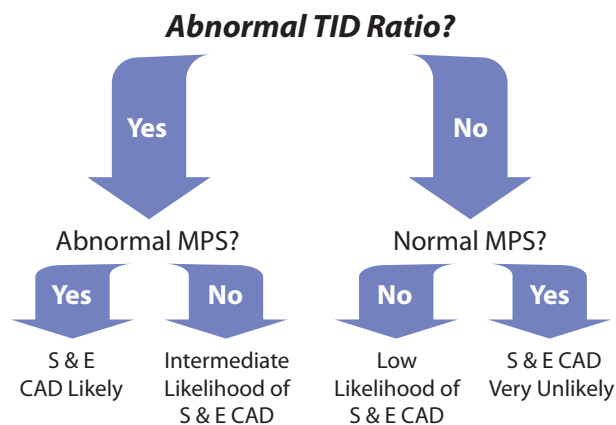
Combining abnormal TID ratios with abnormal MPI results substantially improves the ability to identify patients with severe and extensive CAD. In an algorithm proposed by Abidov et al,¹⁴ patients with both an abnormal TID ratio and abnormal MPI results have a high likelihood of severe and extensive CAD, and they should be considered for coronary angiography and possible revascularization. If both markers are negative, patients have a low probability of severe and extensive CAD and might be candidates for medical management without coronary angiography. Patients who have 1 positive marker have an intermediate likelihood of severe and extensive CAD and additional information is probably needed to make a diagnosis (Figure 2).

Patient management decisions should not be based solely on a finding of TID. When integrated with other clinical information (eg, typical angina, advanced age, diabetes), TID can be useful in selecting patients as candidates for further noninvasive testing or coronary angiography.⁴

References

1. Duarte PS, Smanio PE, Oliveira CA, Martins LR, Mastrocolla LE, Pereira JC. Clinical significance of transient left ventricular dilation assessed during myocardial Tc-99m sestamibi scintigraphy. *Arq Bras Cardiol.* 2003;81:479-482.
2. Burrell S, MacDonald A. Artifacts and pitfalls in myocardial perfusion imaging. *J Nucl Med Technol.* 2006;34:193-211.
3. Kinoshita N, Sugihara H, Adachi Y, et al. Assessment of transient left ventricular dilation on rest and exercise on Tc-99m tetrofosmin myocardial SPECT. *Clin Nucl Med.* 2002;27:34-39.
4. Abidov A, Bax JJ, Hayes SW, et al. Transient ischemic dilation ratio of the left ventricle is a significant predictor of future cardiac events in patients with otherwise normal myocardial perfusion SPECT. *J Am Coll Cardiol.* 2003;42:1818-1825.
5. Mazzanti M, Germano G, Kiat H, et al. Identification of severe and extensive coronary artery disease by automatic measurement of transient ischemic dilation of the left ventricle in dual-isotope myocardial perfusion SPECT. *J Am Coll Cardiol.* 1996;27:1612-1620.
6. McClellan JR, Travin MI, Herman SD, et al. Prognostic importance of scintigraphic left ventricular cavity dilation during intravenous dipyridamole technetium-99m sestamibi myocardial tomographic imaging in predicting coronary events. *Am J Cardiol.* 1997;79:600-605.
7. Doukky R, Hendel RC. Practical guide to risk stratification using myocardial perfusion imaging. In: Heller GV, Hendel RC, eds. *Nuclear Cardiology: Practical Applications.* New York, NY: McGraw-Hill Companies; 2004:259-274.
8. Iskandrian A, Heo J, Nguyen T, Lyons E, Paugh E. Left ventricular dilatation and pulmonary thallium uptake after single-photon emission computer tomography using thallium-201 during adenosine-induced coronary hyperemia. *Am J Cardiol.* 1990;66:807-811.
9. Al-Senan, Staff RT. The origins of transient ischemic dilation in SPECT imaging. Presentation at International

Figure 2. Simplified clinical algorithm for implementing combined assessment of perfusion and TID.



TID=transient ischemic dilation, MPS=myocardial perfusion SPECT, S=severe, E=extensive.

Adapted from Abidov A et al.¹⁴

SUMMARY

It has been reported that TID is an important finding that can help to avoid false negatives on stress MPI due to balanced, multivessel ischemia. Because it serves as an accurate marker for severe and extensive multivessel CAD, it may be a clinically useful diagnostic tool. As an accurate predictor of future cardiac events, it may provide prognostic value in identifying patients at high risk. TID is easy to assess and is most useful when integrated with other clinical information and interpretation of MPI results.

For interactive *Tech Tips* and more, visit pharmstresstech.com.

10. Takeishi Y, Tono-oka I, Ikeda K, Komatani A, Tsuiji K, Yasui S. Dilatation of the left ventricular cavity on dipyridamole thallium-201 imaging: a new marker of triple-vessel disease. *Am Heart J.* 1991;121:466-475.
11. McLaughlin MG, Danias PG. Transient ischemic dilation: a powerful diagnostic and prognostic finding of stress myocardial perfusion imaging. *J Nucl Cardiol.* 2002;9:663-667.
12. Weiss AT, Berman DS, Lew AS, et al. Transient ischemic dilation of the left ventricle on stress thallium-201 scintigraphy: a marker of severe and extensive coronary artery disease. *J Am Coll Cardiol.* 1987;9:752-759.
13. Hung GU, Lee KW, Chen CP, Lin WY, Yang KT. Relationship of transient ischemic dilation in dipyridamole myocardial perfusion imaging and stress-induced changes of functional parameters evaluated by TI-201 gated SPECT. *J Nucl Cardiol.* 2005;12:268-275.
14. Abidov A, Bax JJ, Hayes SW, et al. Integration of automatically measured transient ischemic dilation ratio into interpretation of adenosine stress myocardial perfusion SPECT for detection of severe and extensive CAD. *J Nucl Med.* 2004;45:1999-2007.
15. Abidov A, Berman DS. Transient ischemic dilation associated with poststress myocardial stunning of the left ventricle in vasodilator stress myocardial perfusion SPECT: True marker of severe ischemia? *J Nucl Cardiol.* 2005;12:258-260.
16. Marcassa C, Galli M, Baroffio C, Campini R, Giannuzzi P. Transient left ventricular dilation at quantitative stress-rest sestamibi tomography: clinical, electrocardiographic, and angiographic correlates. *J Nucl Cardiol.* 1999;6:397-405.
17. Lette J, Lapointe J, Waters D, Cerino M, Picard M, Gagnon A. Transient left ventricular cavity dilation during dipyridamole-thallium imaging as an indicator of severe coronary artery disease. *Am J Cardiol.* 1990;66:1163-1170.

Provided as an educational service by **Astellas Pharma US, Inc.**

COMMITTED TO CARDIOLOGY®